



Feasibility and Safety of Ipsilateral Ulnar Access in Cases of Impossibility or Failure of Radial Access for Coronary Angiography or Percutaneous Coronary Intervention

Paulo Vinicios Falcão Duarte, MD¹; Leandro Assunção Cortes, MD¹; Fernanda Barbosa de Almeida Sampaio, MD¹; Julia Machado Barroso, MD²; Gustavo Medeiros da Silveira, MD¹; Gibran Bhering Nascif, MD¹; Ariovaldo Oliveira Filho, MD¹; Marcelo Lemos Ribeiro, MD¹; Marcos Mendes Salles, MD¹; Andrea De Lorenzo, MD, PhD³

Abstract

Objectives. To evaluate the feasibility and safety of using the ulnar access in coronary angiography and percutaneous coronary intervention, in the failure or contraindication of ipsilateral radial access. **Methods.** We prospectively evaluated, in a quaternary hospital, patients undergoing coronary angiography or percutaneous coronary intervention by transulnar approach, in case of failure or contraindication to the ipsilateral radial access. **Results.** Between August 2018 and March 2020, of the 5,916 invasive coronary procedures performed, 2.2% were by transulnar approach. In the 130 patients evaluated, the indication for use of the transulnar approach was predominantly the low-amplitude or difficult to palpate radial pulse when compared to the ulnar artery (39.2%), followed by occlusion of the ipsilateral radial artery (33.1%). Complications of using the transulnar approach were superficial hematoma or low-degree muscle infiltration with extension ≤ 10 cm, in 6 patients (4.5%), and in 5 cases (3.8%) hematoma > 10 cm. There was a case of transient ischemia of the hand due to forearm hematoma, treated conservatively. No cases of arterial thrombosis, pseudoaneurysm, arteriovenous fistula, symptomatic ulnar artery occlusion or ulnar nerve injury were observed after 30 days follow-up. **Conclusion.** The use of ipsilateral transulnar access is a feasible and safe alternative in cases where radial access would be impossible. This access site is associated with a low incidence of complications, which, when present, are most commonly associated with the occurrence of spasm after the attempted radial puncture.

J INVASIVE CARDIOL 2022;34(2):xx-xx.

Key words: ulnar artery, cardiac catheterization, percutaneous transluminal coronary angioplasty

Hemodynamic examinations and procedures in cardiology are very frequent worldwide, with 480,000 coronary angioplasties performed in the US in 2014.¹ Initially, cardiac catheterizations were performed using the brachial or femoral approaches; however, due to frequent complications such as localized bleeding, and the need to stay longer in the hospital, causing additional costs, other approaches were developed.^{2,3}

Over the past two decades, radial access approaches have shown themselves to be safer than femoral approaches for percutaneous coronary procedures, as they diminish the risk of

vascular complications, length of hospitalization, and hospital costs, increase patient comfort, and reduce time.^{2,4}

Even though transradial access is the first choice in hemodynamic studies, this access route also has limitations, including the propensity for vasospasm, the smaller vessel size, and a failure rate of up to 10% due to anatomical variations.^{4,5}

The ulnar approach has been proposed as a valid access site for coronary procedures, with similar viability and safety compared to radial access, as it is frequently larger, less tortuous, and has fewer anatomical variations, such as loops and stenoses. It also

has a lower propensity for spasms. Furthermore, it provides an adequate route in patients who will need confection of an arteriovenous fistula for hemodialysis or myocardial revascularization in the future.⁶

In the case of failure during insertion of the radial artery sheath by the interventionist cardiologist, changing directly to the ipsilateral ulnar artery as the second choice is viable, avoiding femoral perforation and the associated risks of bleeding. This is due to studies in which angiographs of the forearm have shown the interosseous artery's importance in vascularization of the hand; these studies have shown that, in the case of occlusion or conditions that reduce the blood flow in the radial artery, collateral vessels of the interosseous artery were present, supplying blood to the potentially ischemic region of the hand.^{7,8}

Nevertheless, the ulnar access is rarely used. The femoral access is most frequently chosen as a second option, possibly because of the operators' expertise with the femoral approach, as well as the scarcity of studies demonstrating the safety and efficacy of using ulnar access when the radial fails.

Methods

Study design and population. This study consisted of a prospective, observational cohort of patients submitted to coronary angiography or percutaneous coronary interventions by the ulnar access in case of failure or contraindication to the ipsilateral radial access, at a quaternary hospital in Brazil, between 16 August 2018 and 31 March 2020.

The transulnar procedure was considered eligible if one of the following conditions was found: non-palpable or low amplitude radial pulse when compared to the ulnar artery; occlusion of the ipsilateral radial artery found on physical examination; significant vasospasm after attempted puncture of the radial artery; anatomical variations documented in previous exams, such as loops, stenosis or tortuosity; and the intention of preserving the radial artery for confection of an arteriovenous fistula in chronic kidney disease patients or an arterial graft for myocardial revascularization surgery.

Requirements for transulnar access approach were, the non-feasibility of an ipsilateral radial artery, the presence of palpable ulnar pulse and the presence of both positive reverse Allen's and reverse Barbeau tests. Previous insertion of a sheath in the ipsilateral radial artery during the same procedure was considered to be an exclusion criterion from the study.

Description of the clinical evaluation. The reverse Allen test consisted of simultaneous compression of the ulnar and radial arteries for one to two minutes, followed by decompression of the radial artery. If the pallor of the hand was replaced by flushing within 9 seconds, the integrity of the palmar arch was defined, and the examination considered positive.

The reverse Barbeau test consisted of monitoring the fifth finger with a pulse oximeter, followed by vigorous compression of the ulnar artery for a period of two minutes. If, after the two-minute interval, the pulse tracing did not recover (classification D), the exam was considered negative, and the patient was not considered for the study.

Ulnar arterial puncture. The technique for transulnar puncture was similar to that for transradial puncture. In summary, the palm of the hand was supported in a supine position. After administering local anesthesia with 2% lidocaine, the artery was punctured with a needle or 21-gauge catheter at an angle of 30 to 60 degrees, two centimeters from the pisiform bone. After arterial puncture, a 0.018" guidewire was advanced and a 5 French (Fr) sheath for diagnostic angiography or a 6 Fr sheath for percutaneous coronary intervention (Seldinger technique) was introduced. Anticoagulation was practiced in routine form, using unfractionated heparin (UFH) in doses of 5,000 IU for coronary angiography and 10,000 IU for percutaneous arterial coronary interventions. The administration of vasodilators to avoid vasospasm was determined according to the operator's criteria.

Follow-up. The patients were evaluated clinically within 30 days of the procedure, mostly by the same examiner. An arterial echo Doppler was performed in cases of clinical suspicion of vascular complications. No patients were lost to follow-up.

Complications were considered to be: *arterial thrombosis*, defined as pain, paraesthesia, skin pallor and reduced or absent distal pulses; *pseudoaneurysm*, defined as a pulsatile mass with a systolic murmur over the catheter insertion site; *arterial occlusion*, defined as absence of pulse, skin pallor and pain; *ulnar nerve injury*, defined as pain and or paresthesia of the hand; *hand ischemia*, defined as pain, skin pallor or cyanosis of the hand and *hematoma* classified according to the EASY classification (Hematoma classification after transradial/ulnar PCI) as *Grade I*: local, superficial hematoma of up to 5 cm, *Grade II*: hematoma with moderate muscular infiltration of up to 10 cm, *Grade III*: forearm hematoma and muscular infiltration below the elbow, *Grade IV*: hematoma and muscular infiltration extending above the elbow; and *Grade V*: compartment syndrome.

Outcome. The primary outcome was evaluating the feasibility and safety of using the ulnar access for coronary angiography or percutaneous coronary intervention, through the evaluation of the frequency of complications resulting from the use of the ulnar access, in cases of failure or contraindication of using the ipsilateral transradial access. The vascular complications assessed were: arterial thrombosis, pseudoaneurysm, arteriovenous fistula, arterial occlusion, hand ischemia, ulnar nerve lesion, and hematoma.

Sample size calculation. For our sample size calculation, we considered 9% vascular complications, after convenience sample

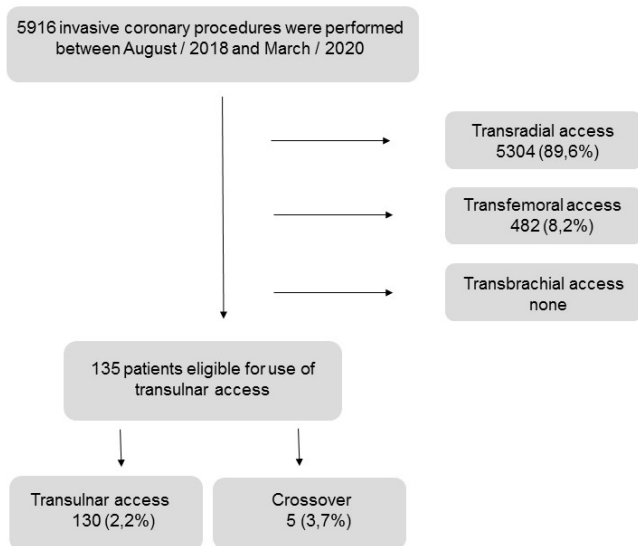


FIGURE 1. Study population flow chart.

analysis, with 5% error and a confidence level of 95%, indicating a minimum number of 126 patients.

Ethics statement. This study conforms to the guiding principles of the Declaration of Helsinki and was approved by the Institutional Committee on Human Research (number 94624518.5.0000.5272). All patients gave written informed consent for participation in the study.

Statistical analysis. Categorical variables were described as absolute numbers and proportions and continuous variables as mean and standard deviation, or median and interquartile range. Chi-square and Fisher’s exact tests were used to calculate the association between categorical variables. The Kolmogorov-Smirnoff test was used to assess the distribution of continuous variables. For the continuous variables that did not present a normal distribution, the Wilcoxon-Mann Whitney test was used, otherwise the Student’s T test. The data were analyzed using the Jamovi 1.2.25 program, adopting a significance level of 5%.

Results

During the study, 5,916 invasive coronary procedures were performed, of which 5,304 (89.6%) were transradial, 482 (8.2%) were transfemoral, and 130 (2.2%) were transulnar. None were brachial (Figure 1). Patients submitted to invasive coronary procedure using the transulnar access were predominantly male, 75 (57.7%), with a median age of 63 ± 9.6 years (Table 1).

All patients using anticoagulants discontinued the drug for a minimum of 48 hours to use new oral anticoagulants and 5 days for warfarin before the procedure.

The procedure was predominantly indicated in the evaluation of stable angina (35.4%), followed by elective coronary angioplasty

TABLE 1. Characteristics of the study population.

Clinical Variables	Patients (n = 130)
Age (years)	63 ± 9.6
Male	75 (57.7%)
Body mass index (kg/m ²)	27.6 (25.4-31.4)
Body mass index ≥30 kg/m ²	42 (32.3%)
Race	
White	73 (57%)
Black	26 (20.3%)
Mixed race	29 (22.7%)
Systemic arterial hypertension	116 (89.2%)
Dyslipidemia	93 (71.5%)
Diabetes mellitus	50 (38.5%)
Family history of early coronary artery disease	37 (28.5%)
Smoking habit	
Current smoker	16 (12.3%)
Former smoker	60 (46.2%)
Chronic kidney failure	11 (8.5%)
Peripheral obstructive arterial disease	8 (6.2%)
Previous acute myocardial infarction	67 (51.5%)
Previous percutaneous coronary revascularization	51 (39.2%)
Previous surgical myocardial revascularization	15 (11.5%)
Previous stroke	9 (6.9%)

Data presented as mean ± standard deviation or number (%).

(30.8%), and unstable coronary artery disease (23.8%). *Ad hoc angioplasty*, defined as coronary angioplasty immediately after diagnostic coronary angiography, occurred in 11.5% of the cases. Among patients eligible for the study, 87 (66.9%) had a history of invasive coronary procedure via the ipsilateral radial artery.

The indication for using transulnar access was the low amplitude or difficult to palpate radial pulse when compared to the ulnar artery (39.2%), followed by occlusion of the ipsilateral radial artery found on physical examination (33.1%) (Figure 2), spasm after attempting to puncture the radial artery (23.8%), and preservation of the radial artery for possible confection of an arteriovenous fistula in patients with chronic kidney disease (3.1%) (Table 2).

The success of the technique was 96.2%, with crossover to contralateral radial or femoral access being justified in four cases due to failure while attempting to puncture the ulnar artery and in one case because of excessive sinuosity in the subclavian artery, making advancement of the 0.035” guidewire impossible.

The majority of procedures were performed using an intro-

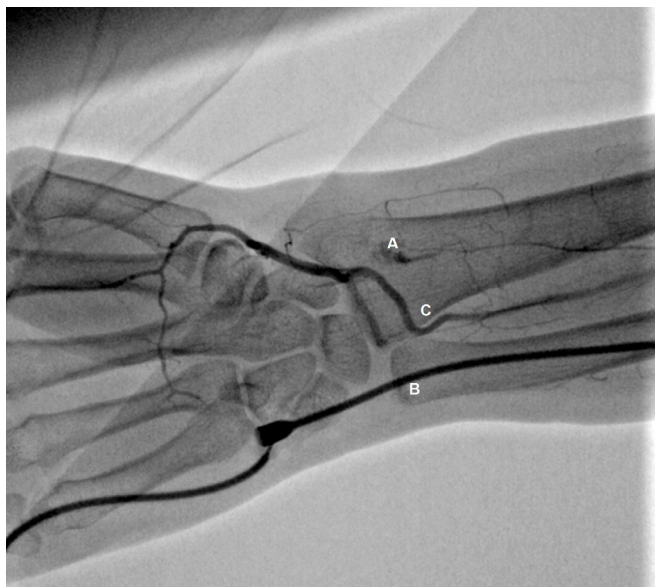

FIGURE 2. Forearm angiography. (A) Chronic radial artery occlusion. (B) Temporary occlusion of the ulnar artery by the sheath. (C) Blood flow from the palmar arch through the anterior interosseous artery.

Variables	Patients (n = 130)
Indication of the procedure	
Assessment of stable angina	46 (35.4%)
Elective angioplasty	40 (30.8%)
Acute coronary syndrome	31 (23.8%)
Preoperative evaluation (before cardiac surgery)	9 (6.9%)
Investigation of heart failure	3 (2.3%)
Indication of the use of ulnar access	
Low amplitude radial pulse	51 (39.2%)
Occlusion of the ipsilateral radial artery	43 (33.1%)
Spasm after attempted puncture of the radial artery	31 (23.8%)
Preservation of the radial artery for making AVF	4 (3.1%)
Anatomical variation of the radial artery	1 (0.8%)
Previous transradial procedure	87 (66.9%)
Previous transulnar procedure	6 (4.6%)
Use of antiplatelet agents	
Acetylsalicylic acid	31 (23.8%)
Clopidogrel	3 (2.3%)
Acetylsalicylic acid plus clopidogrel	81 (62.3%)

Data presented as mean ± standard deviation or number (%).
AVF = arteriovenous fistula.

TABLE 3. Complications related to the use of transulnar access.

Complications	Patients (n = 130)
Transulnar approach failure	5 (3.8%)
Local hematoma	11 (8.5%)
Hematoma EASY 1	2 (1.5%)
Hematoma EASY 2	4 (3.0%)
Hematoma EASY 3	5 (3.8%)
Hematoma EASY 4	0 (0.0%)
Hematoma EASY 5	0 (0.0%)
Transient ischemia of the hand	1 (0.7%)
Symptomatic ulnar artery occlusion	0 (0.0%)
Ulnar artery thrombosis	0 (0.0%)
Ulnar artery pseudoaneurysm	0 (0.0%)
Arteriovenous fistula	0 (0.0%)
Ulnar nerve injury	0 (0.0%)

Data presented as number (%).

ductory 6-Fr sheath (57.6%). In 75 patients (57.7%), only coronary angiography was performed and 5,000 IU of NFH intra-arterially was administered. Fifty-five (42.3%) were submitted to elective or *ad hoc* coronary angioplasty, receiving 10,000 IU NFH intra-arterially. The median duration of coronary angiography was 16 (12–30) minutes and 40 (27.5–60) minutes for coronary angioplasty. The mean of catheters used was 2 ± 0.9 .

Complications using transulnar access were predominantly superficial hematoma or low muscular infiltration with ≤ 10 cm extension in six patients (4.5%), and in five cases (3.8%), a hematoma > 10 cm affecting the forearm below the elbow was observed. There was one case of transitory hand ischemia after the hematoma on the forearm, which was treated conservatively by heating the hand, reversion of the effect of anticoagulation using protamine and intermittent inflation of the sphygmomanometer on the forearm in a patient for whom transulnar access was chosen after spasm during the attempt to puncture the radial artery.

No cases of arterial thrombosis, pseudoaneurysm, arteriovenous fistula, symptomatic occlusion of the ulnar artery, or lesion of the ulnar nerve were observed within 30 days of follow-up (**Table 3**).

Although higher rates of complications are observed in female patients and in the use of dual antiplatelet therapy, these associations were not statistically significant (**Table 4**). Among the variables related to the procedure, there was significant association between complications and spasms after attempts to puncture the radial artery ($P=0.022$) (**Table 5**).

TABLE 4. Association between clinical variables and complications.

Clinical Variables	Complications	P-Value
Gender		.05
Male	3 (27.3%)	
Female	8 (72.7%)	
Body mass index ≥ 30 kg/m ²	2 (18.2%)	.50
Age >70 years	4 (36.4%)	.09
Systemic arterial hypertension	11 (100%)	.22
Diabetes mellitus	5 (45.5%)	.61
Chronic kidney failure	1 (9.1%)	>.99
Smoking	2 (18.2%)	.62
Previous acute myocardial infarction	5 (45.5%)	.76
Previous percutaneous coronary revascularization	4 (36.4%)	.83
Previous surgical myocardial revascularization	2 (18.2%)	.47
Use of acetylsalicylic acid + clopidogrel	10 (90.9%)	.05

Data presented as number (%).

Discussion

In this study, the transulnar approach showed to be a safe and feasible alternative when the ipsilateral radial artery was not accessible. High rates of arterial cannulation success were obtained with low rates of complications, with a predominance of minor bleeding treated conservatively, enabling the patient to have the same benefits offered by the transradial pathway, such as comfort and early ambulation.

Despite the vascular complication rate of 9.2%, there was no major bleeding. There was only one case of transient ischemia of the hand, treated conservatively and with resolution in a few minutes.

The results are similar to the study by Kedeve et al, who evaluated 240 patients undergoing coronary (80%) or carotid (17%) interventions by transulnar approach, with the ipsilateral radial artery occluded and documented by forearm angiography. In that study, there was a crossover rate of 3%, local hematoma in 8% and only 2 patients developed larger hematoma, with muscle infiltration exceeding the elbow. No hand ischemia or ulnar nerve injury were observed. Asymptomatic occlusion of the ulnar artery was found in 3.1% in one month of follow-up.⁹

The risk of formation of local hematoma is probably due to the difficulty in doing the local hemostasis, because of deeper location of the ulnar artery and because there is no rigid surface, such as bone structure, to perform the compressive dressing, unlike what is found in the radial artery access.

TABLE 5. Association between procedural variables and complications.

Procedure Variables	Complications	P-Value
Indication of the use of ulnar access		
Low amplitude radial pulse	2 (18.2%)	.33
Occlusion of the ipsilateral radial artery	3 (27.3%)	.52
Spasm after attempted puncture of the radial artery	6 (54.5%)	.02
Procedure		
Elective coronary angioplasty	6 (54.5%)	.39
Ad hoc angioplasty	2 (18.2%)	.61
Arterial sheath diameter 6 Fr	8 (72.7%)	.35
Number of catheters used >2	5 (45.5%)	.06
Unfractionated heparin 10,000 IU	6 (54.5%)	.39
Procedure time >30 minutes	8 (72.7%)	.11

Data presented as number (%).

In the present study, there was a non-significant tendency towards complications in female patients, which can be justified by the smaller diameter of the ulnar artery in this group. Dharma et al evaluated the diameter of the radial and ulnar arteries by ultrasound of the distal third of the forearm in 1706 patients undergoing interventional cardiology procedures. In the subgroup analysis, a smaller diameter of the radial (2.6 x 2.8 mm, $P < .001$) and ulnar (2.2 x 2.5, $P < .001$) arteries was observed in female patients.¹⁰

Hsueh et al evaluated 87 patients submitted to coronary intervention by the ulnar pathway, with ipsilateral radial occlusion confirmed with forearm angiography. At the 33-month follow-up, no occlusion of the ulnar artery, hand ischemia or severe complications requiring surgery or blood transfusion were observed, only 2.3% of the patients presented hematoma > 5 cm.⁷

Rodríguez-Olivares evaluated the vascular anatomy of the forearm of a small sample of 14 patients submitted to transulnar approach, whose radial artery was occluded. During forearm angiography, it was evidenced that the patients presented simultaneous occlusion of the radial (chronic occlusion) and ulnar arteries (temporary occlusion due to insertion of the introducer sheath). Despite the two occluded arteries, no patient presented signs or symptoms of acute ischemia of the hand during the procedure, because the palmar arch was vascularized by small collaterals, all originating from the interosseous artery and leading to more than one region of the hand. More often, the collaterals were emitted to the radial artery, in the distal portion of the occlusion, with direct insertion to the palmar arch. After 26 months of follow-up, all patients maintained the previous ulnar pulse and no signs of hand ischemia or ulnar nerve injury

were observed. These results suggest that the development of collaterals occur acutely.¹¹

Finally, the findings of the present study may contribute to possible changes in the scenario of interventional cardiology. Bertrand et al evaluated, through a questionnaire, the routine of 1,107 interventional cardiologists from 75 countries. The result showed that the second route of choice in the failure of radial access was the femoral approach (54%), followed by contralateral radial (31%), ipsilateral brachial (10.4%) and ipsilateral ulnar in only 3.3%.¹² With the demonstration of safety and feasibility of ulnar access, this proportion can be changed, aiming to reduce the use of femoral access, the time for ambulation, increase patient comfort.

Conclusion

The use of ipsilateral transulnar access is a feasible and safe alternative in cases of impossibility of radial access, with a low incidence of complications, which, when present, are associated with the occurrence of spasm after the attempted radial puncture.

Study limitations. This was a single-center study, with all procedures performed at a specialized cardiology hospital; therefore, the results may not be representative of other scenarios, such as general hospitals. In addition, the low number of complications limits the investigation of the independent associations between clinical and procedural variables with outcomes by means of multivariable analyses.

References

- Virani SS, Alonso A, Benjamin EJ, et al. Heart disease and stroke statistics-2020 update: a report from the American Heart Association. *Circulation*. 2020;141:e139-1596.
- Wagener JF, Rao SV. A comparison of radial and femoral access for cardiac catheterization. *Trends Cardiovasc Med*. 2015;25:707-713.
- Ewen EF, Zhao L, Kolm P, et al. Determining the in-hospital cost of bleeding in patients undergoing percutaneous coronary intervention. *J Interv Cardiol*. 2009;22:266-273.
- Mason PJ, Shah B, Tamis-Holland JE, et al. An Update on Radial Artery Access and Best Practices for Transradial Coronary Angiography and Intervention in Acute Coronary Syndrome: A Scientific Statement From the American Heart Association. *Circ Cardiovasc Interv*. 2018;11:e000035.
- Kar S. Transulnar cardiac catheterization and percutaneous coronary intervention: techniques, transradial comparisons, anatomical considerations, and comprehensive literature review. *Catheter Cardiovasc Interv*. 2017;90:1126-1134.
- Fernandez R, Zaky F, Ekmejian A, Curtis E, Lee A. Safety and efficacy of ulnar artery approach for percutaneous cardiac catheterization: Systematic review and meta-analysis. *Catheter Cardiovasc Interv*. 2018;91:1273-1280.
- Hsueh SK, Cheng CI, Fang HY, et al. Feasibility and safety of transulnar catheterization in ipsilateral radial artery occlusion. *Int Heart J*. 2017;58:313-319.
- Agostoni P, Zuffi A, Faurie B, et al. Same wrist intervention via the cubital (ulnar) artery in case of radial puncture failure for percutaneous cardiac catheterization or intervention: the multicenter SWITCH registry. *Int J Cardiol*. 2013;169:52-56.
- Kedev S, Zafirovska B, Dharma S, Petkoska D. Safety and feasibility of transulnar catheterization when ipsilateral radial access is not available. *Catheter Cardiovasc Interv*. 2014;83:E51-E60.
- Dharma S, Kedev S, Patel T, Rao SV, Bertrand OF, Gilchrist IC. Radial artery diameter does not correlate with body mass index: A duplex ultrasound analysis of 1706 patients undergoing transradial catheterization at three experienced radial centers. *Int J Cardiol*. 2017;228:169-172.
- Rodríguez-Olivares R, García-Touchard A, Fernández-Díaz JA, Oteo JF, Zorita B, Goicolea Ruigómez J. Transulnar approach with ipsilateral radial occlusion: forearm vascular anatomical description and long-term follow-up. *Rev Esp Cardiol (Engl Ed)*. 2014;67:854-855.
- Bertrand OF, Rao SV, Pancholy S, et al. Transradial approach for coronary angiography and interventions: results of the first international transradial practice survey. *JACC Cardiovasc Interv*. 2010;3:1022-1031.

From the ¹Interventional Cardiology Department, Instituto Nacional de Cardiologia, Rio de Janeiro, Brazil; ²Radiology Department, Rede D'Or São Luiz, Rio de Janeiro, Brazil; and ³Research and Teaching Department, Instituto Nacional de Cardiologia, Rio de Janeiro, Brazil.

Disclosure: The authors have completed and returned the ICMJE Form for Disclosure of Potential Conflicts of Interest. The authors report no conflicts of interest regarding the content herein.

Manuscript accepted May 5, 2021.

The authors report patient consent for image used herein.

Address for correspondence: Paulo Vinícius Falcão Duarte, Interventional Cardiology Department, Instituto Nacional de Cardiologia, Rua das Laranjeiras, 374, Rio de Janeiro, Brazil 22240-006. Email: pv_falcao@hotmail.com